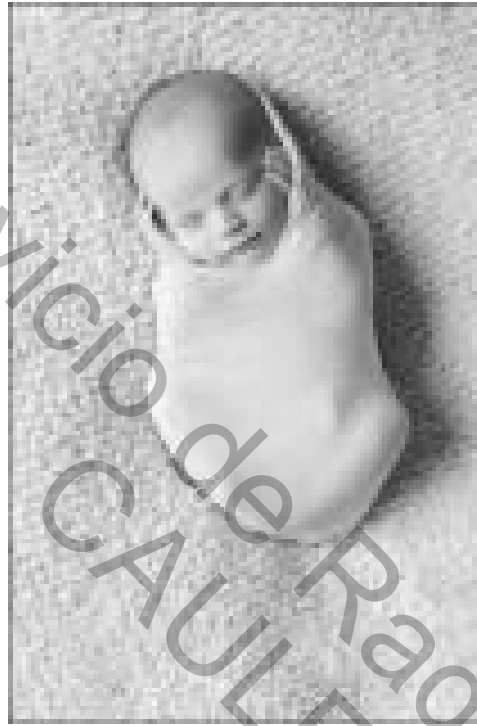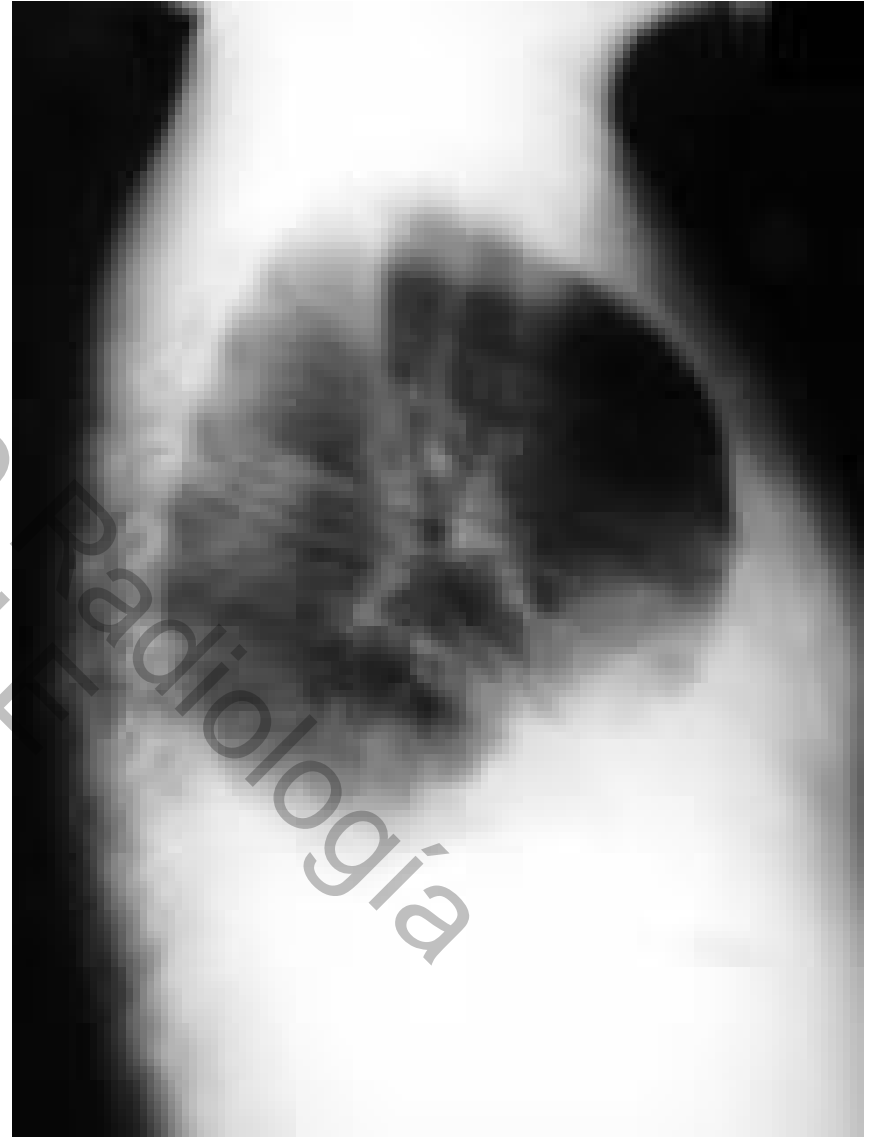
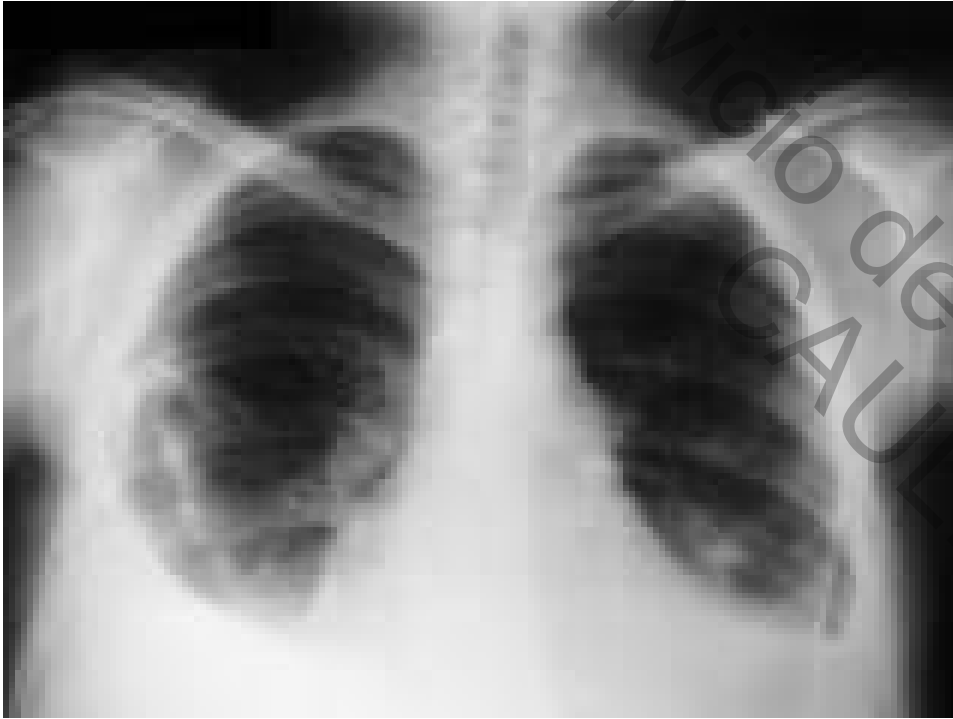
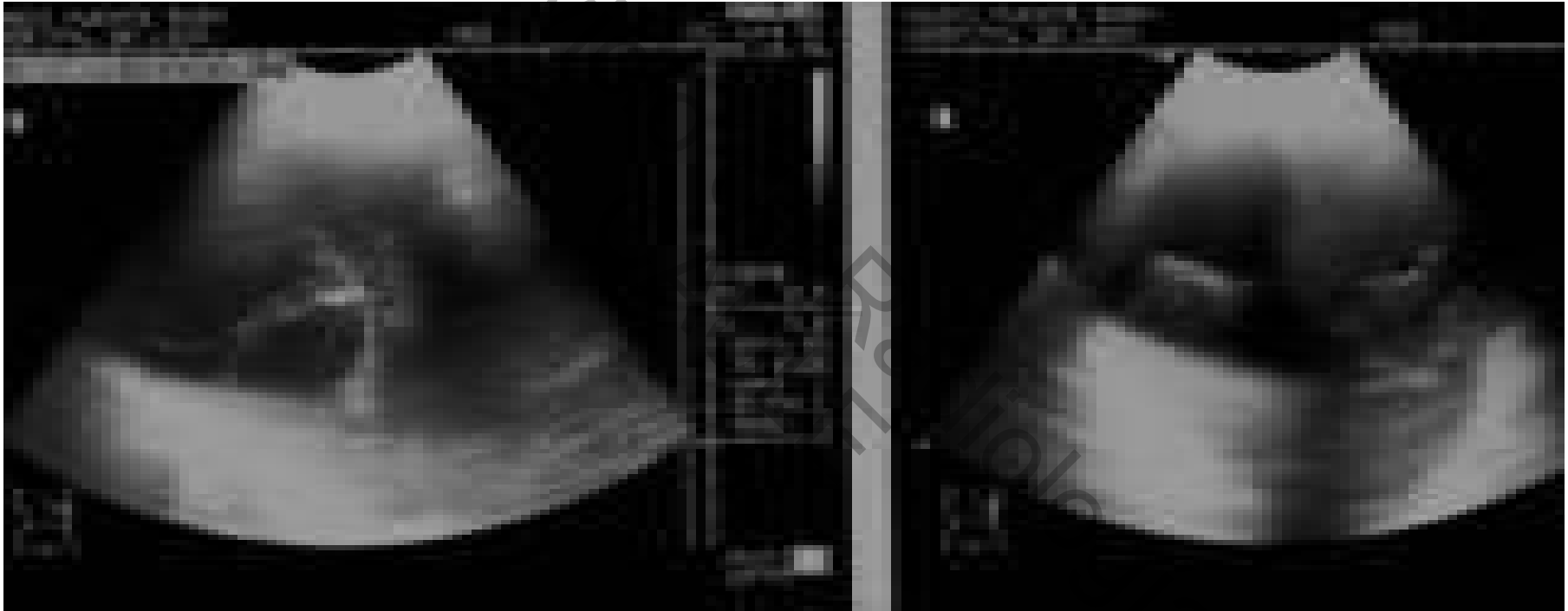


Sesión RX-MI 27/10/10
Luis Martínez Blanco

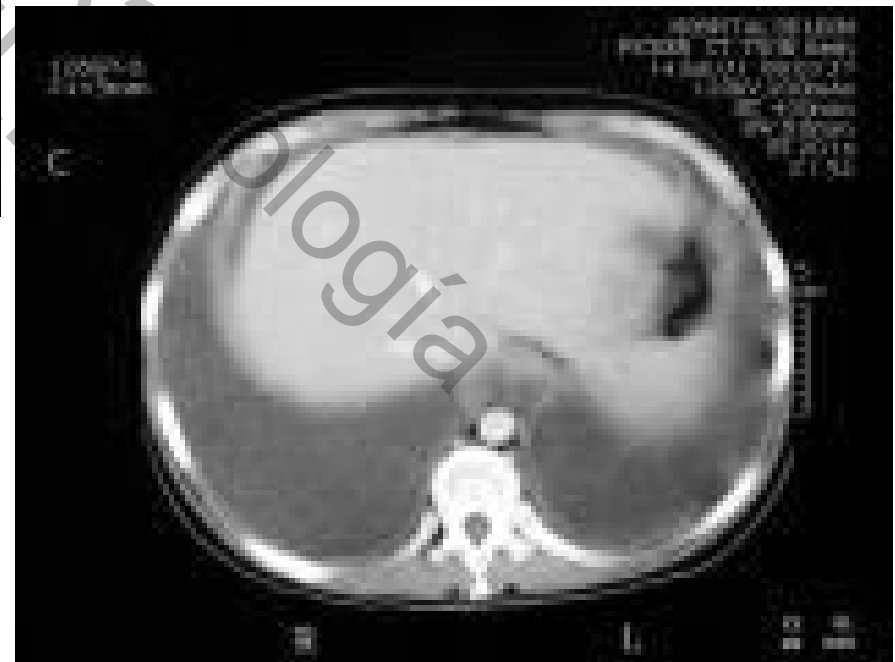
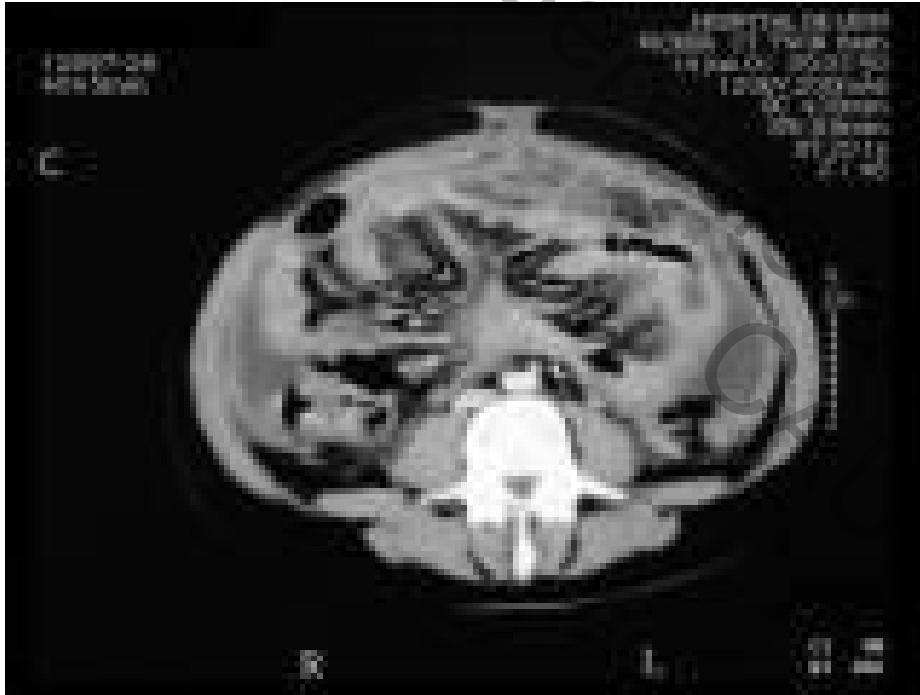

Servicio de
C.A.U.
Radiología

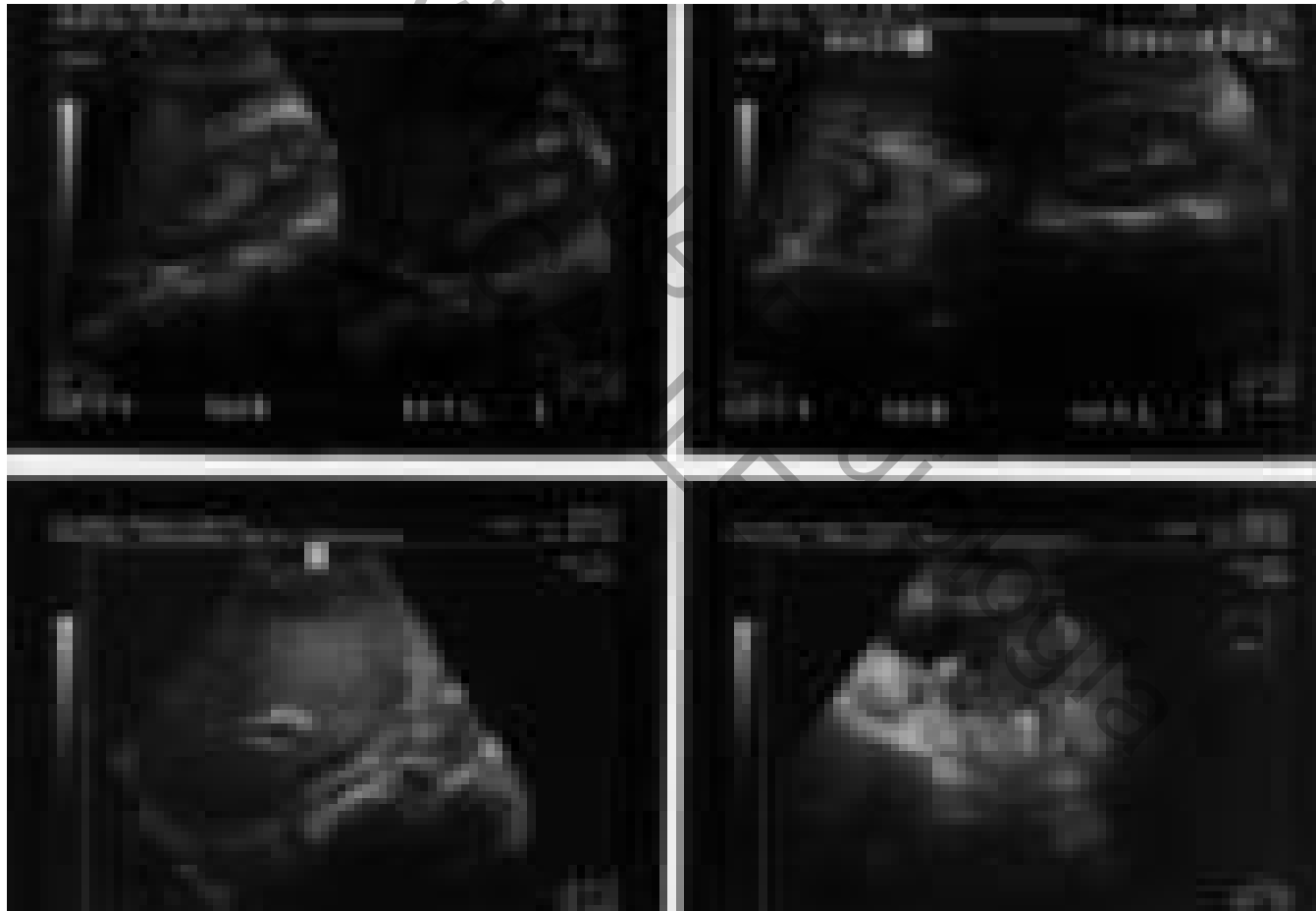6/ 2001



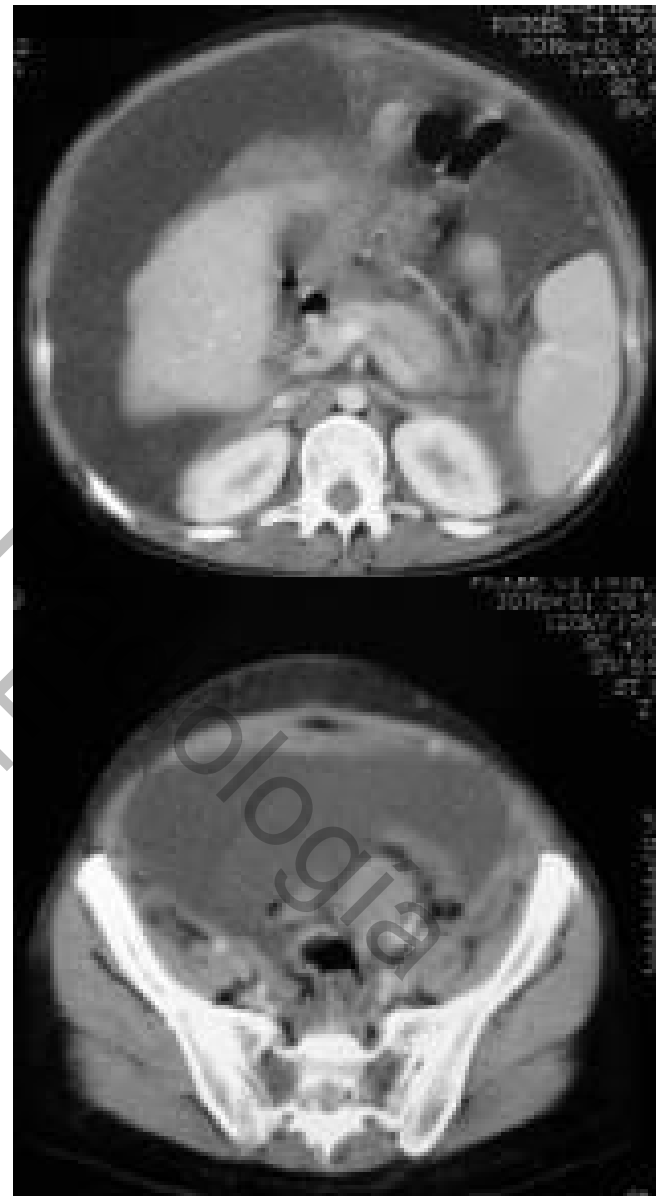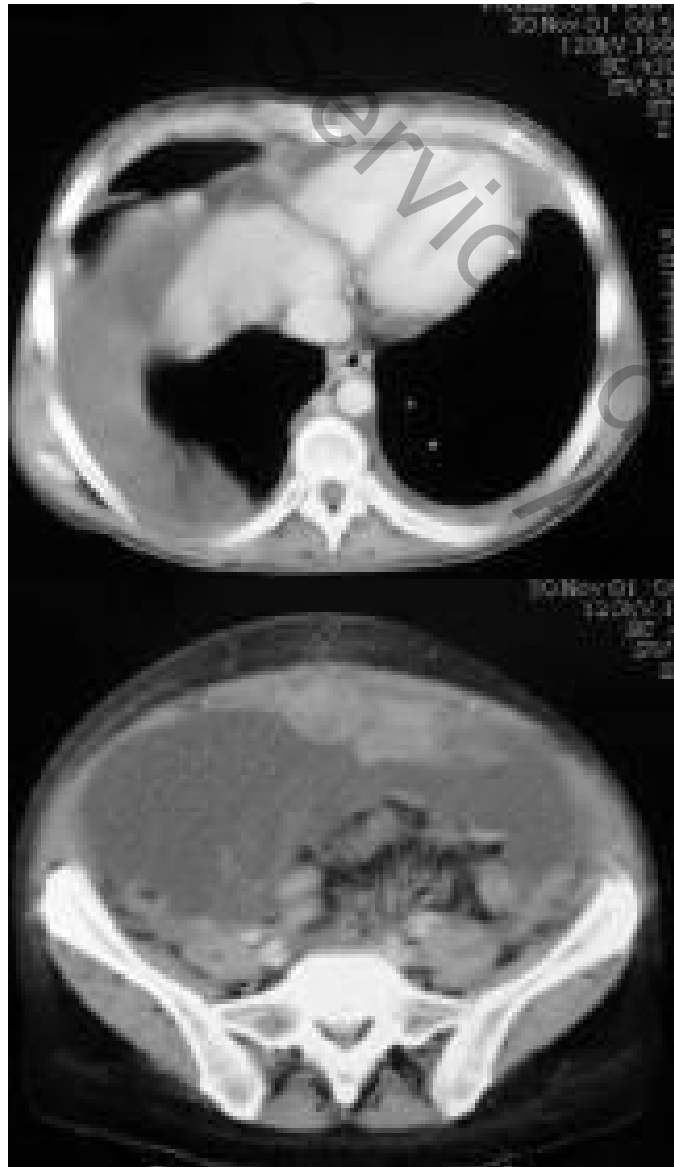
6/2001



9/2001



11/01



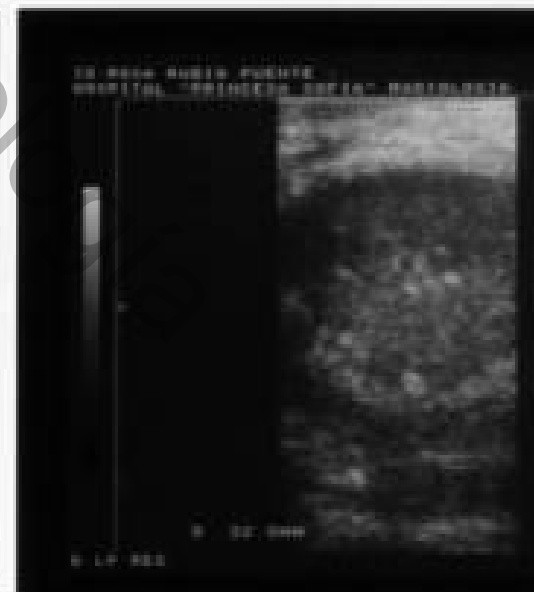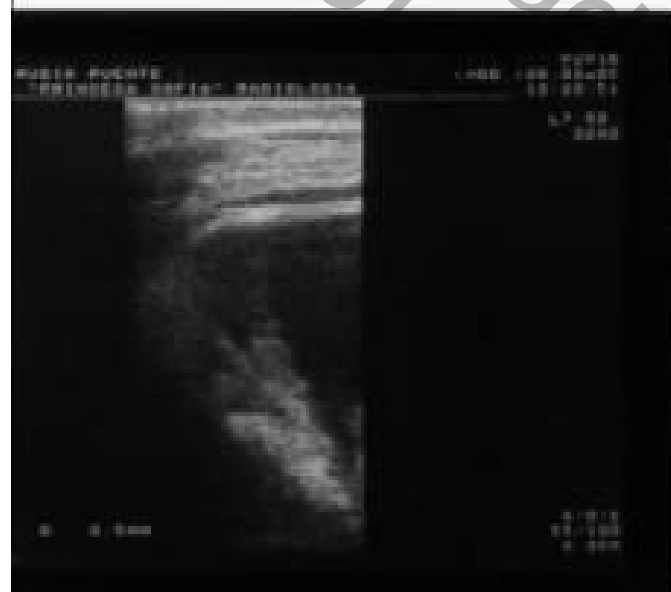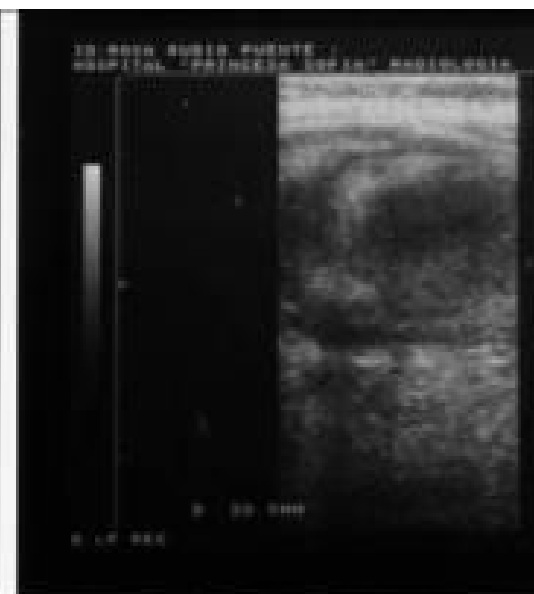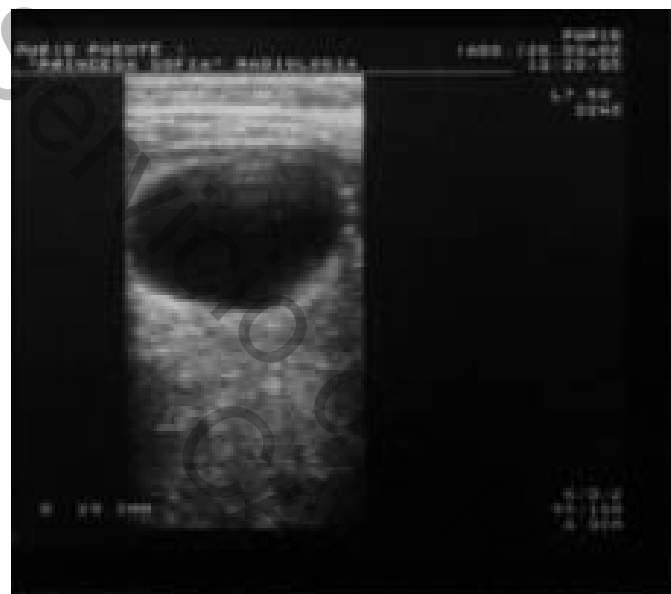Masas abdominales + ascitis

- Infecciosas/inflamatorias
 - Peritonitis tuberculosa.
 - Enfermedad inflamatoria peritoneal
 - Paniculitis mesentérica
 - Mesenteritis retractil
 - Endometriosis.
 - Peritonitis granulomatosa a cuerpo extraño.
 - Fibromatosis mesentérica (cirugía, estrógenos, prostaglandina,..)

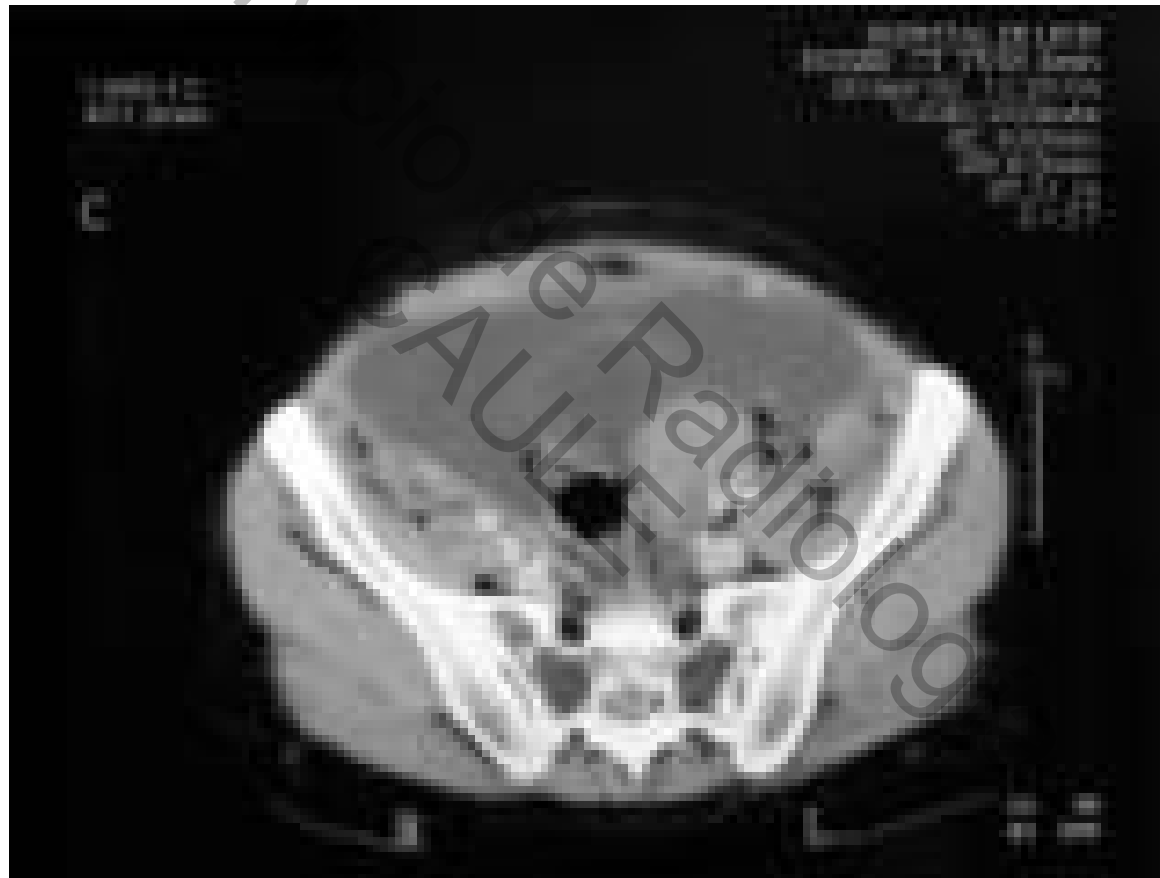Masas abdominales + ascitis

- Tumorales:
 - Metástasis (tumores abdominales y extraabdominales) OVARIO?
 - Pseudomixoma
 - Mesoteliomas
 - T. desmoplásico de célula redondas, pequeñas y azules (TDCR).
 - Leiomiosarcomatosis.
 - Quistes, tumores de epiplon, mesenterio (desmoides),...

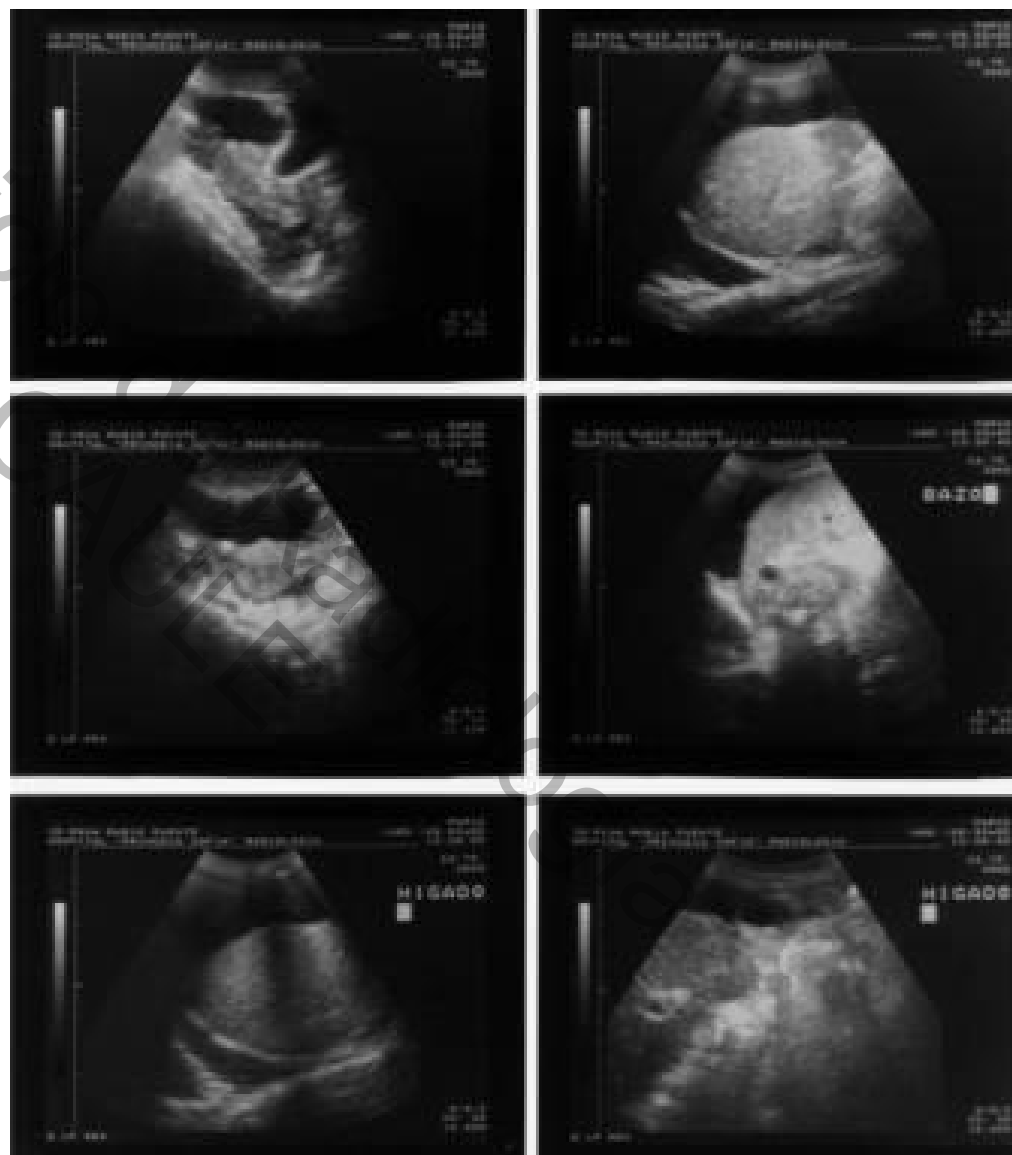
3/ 2002



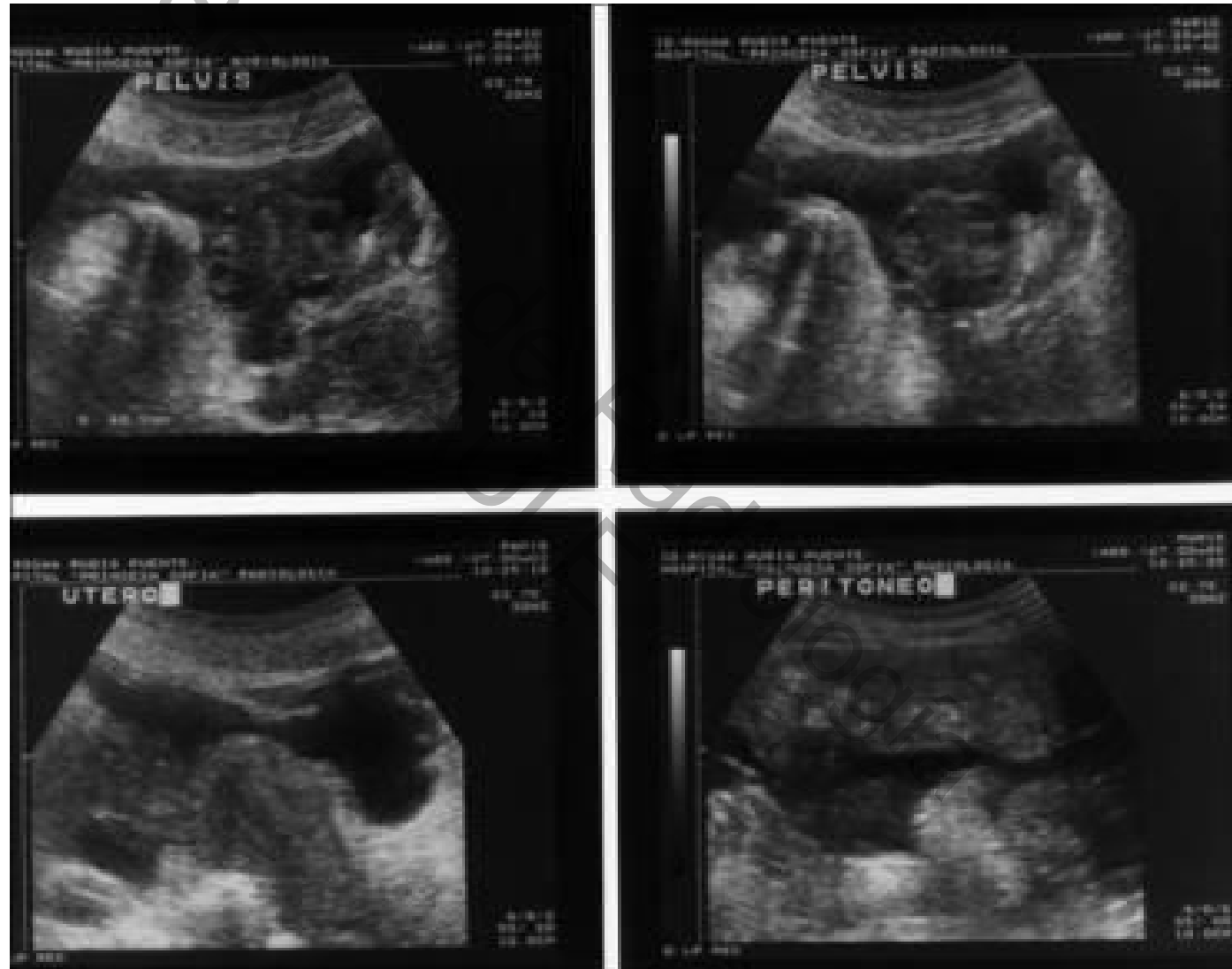4/02



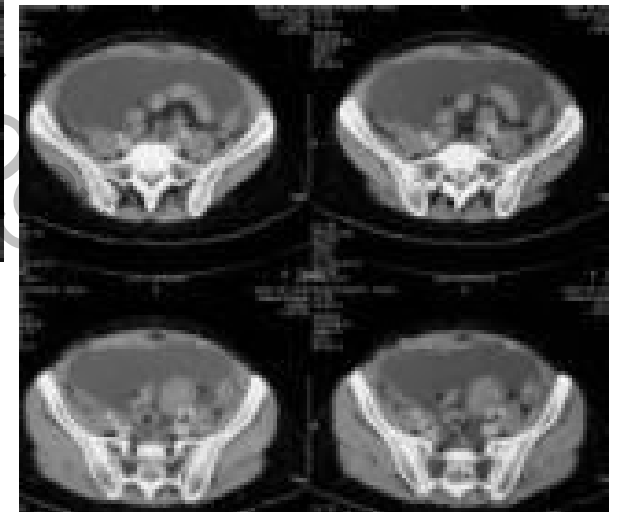
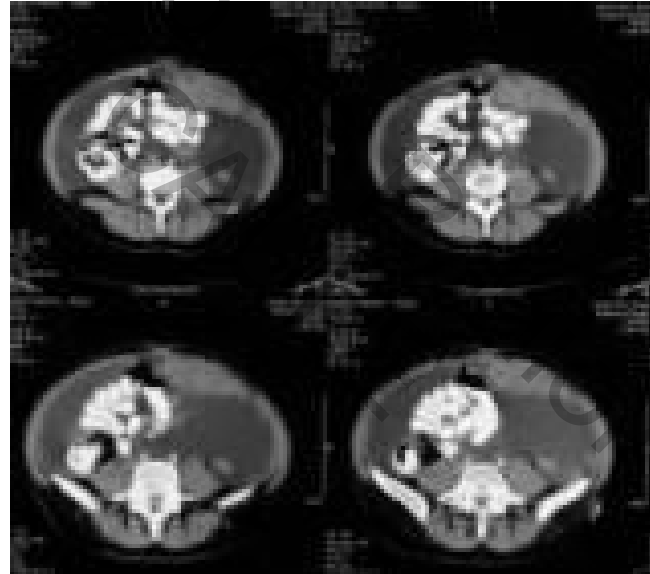
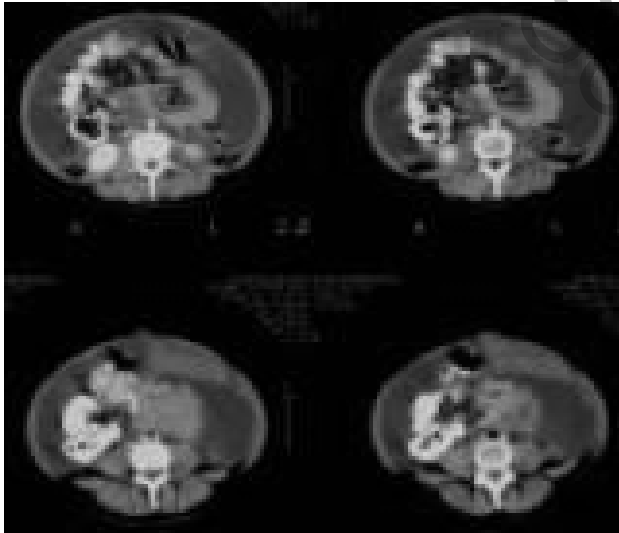
6/ 2002



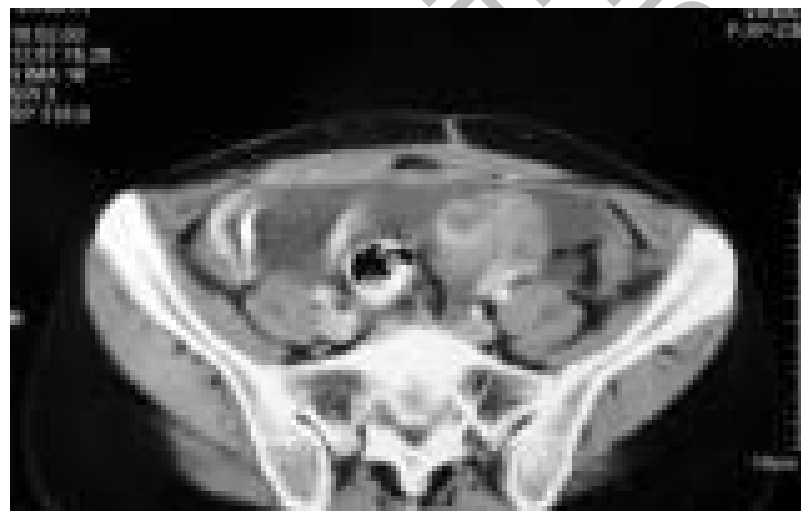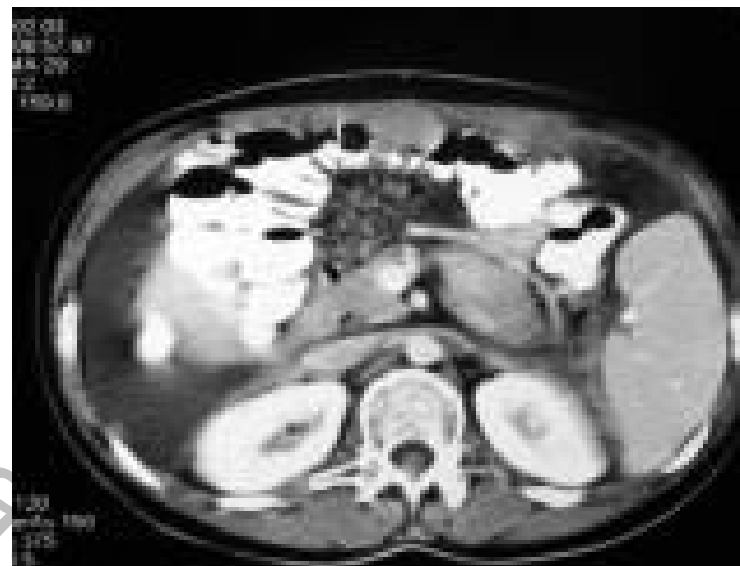
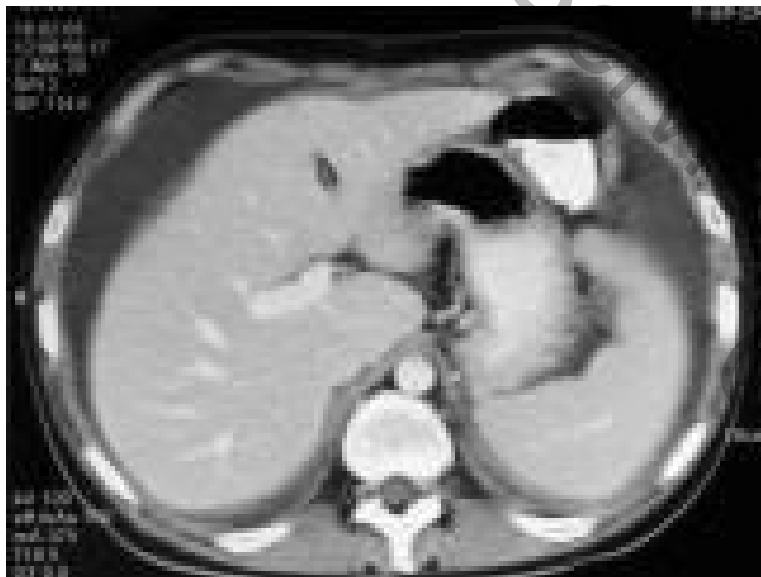
8/ 2002



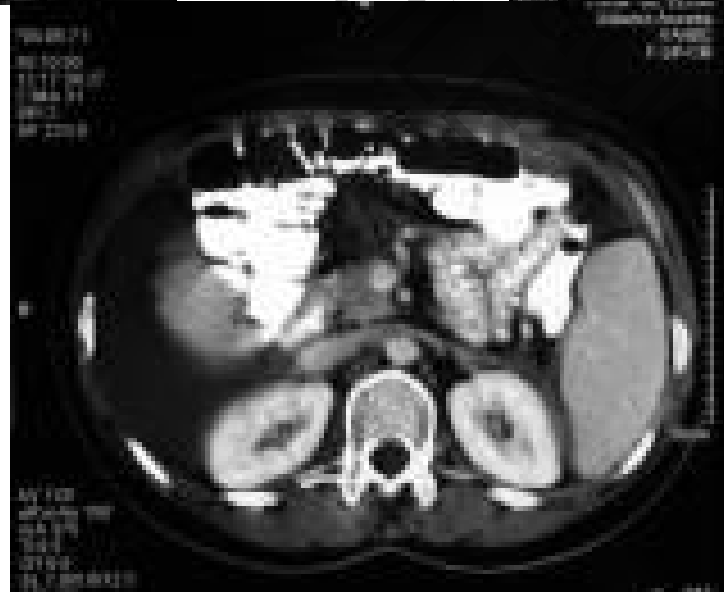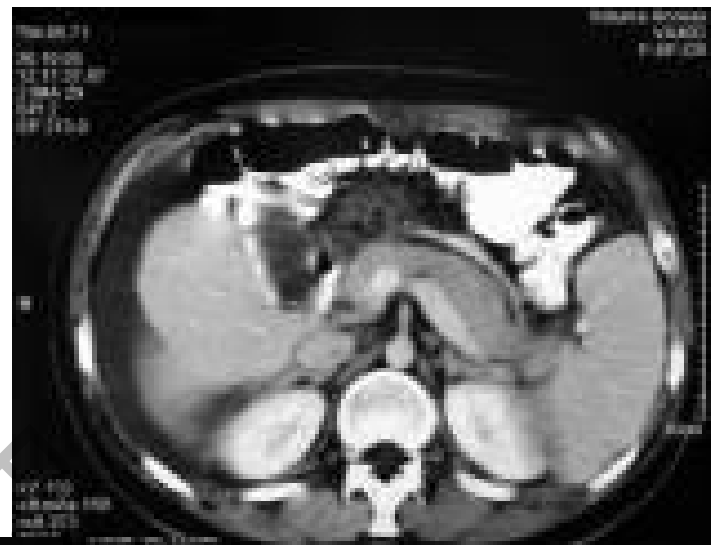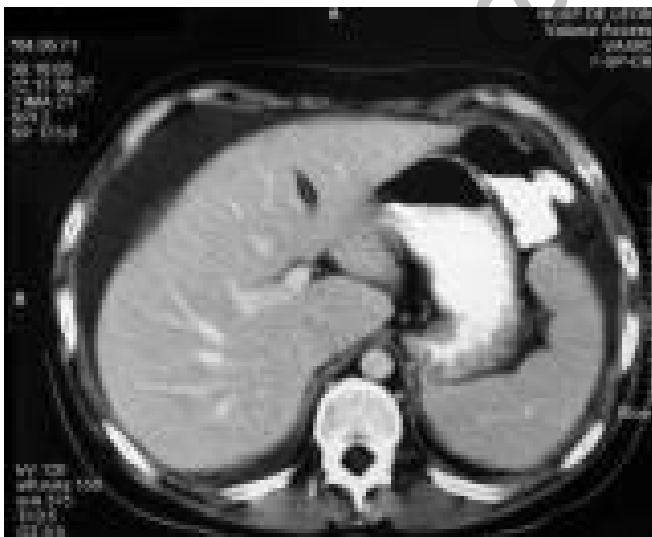
8/2002



2/03



10/03

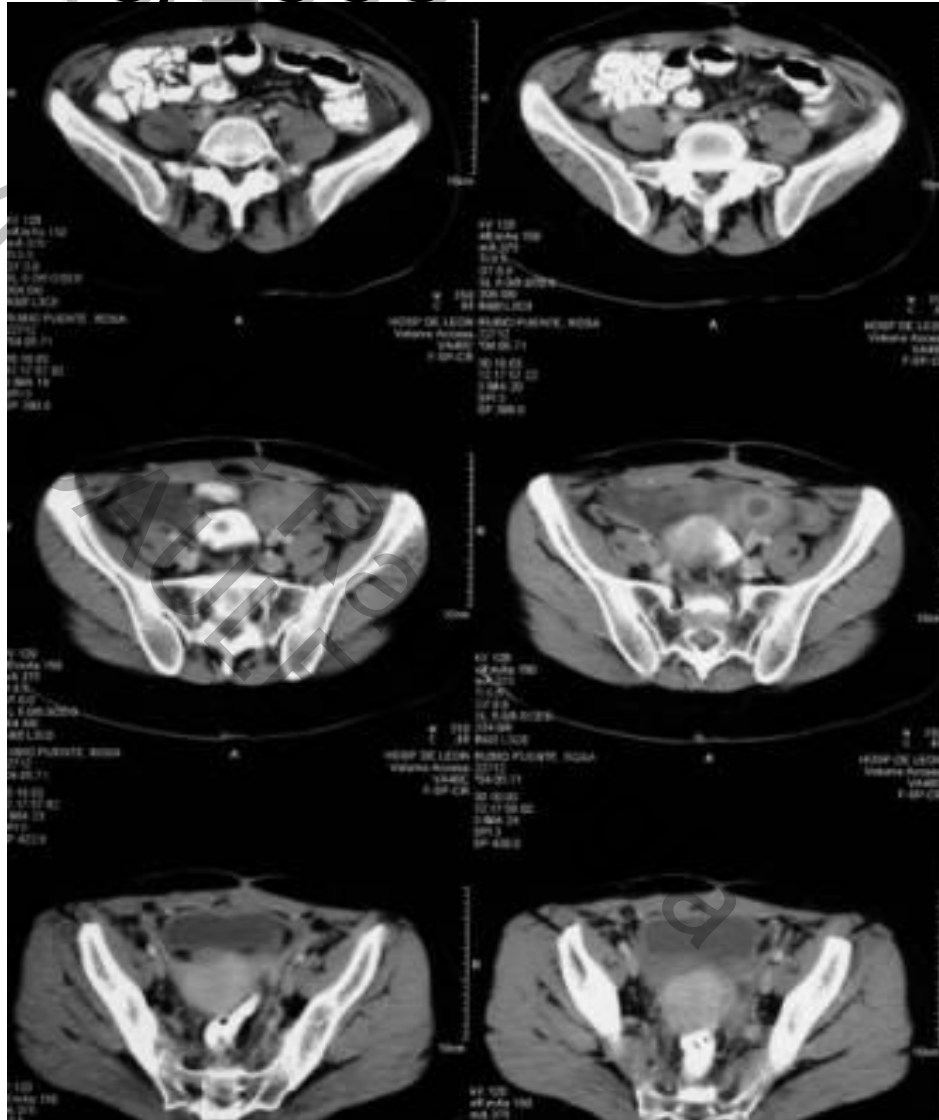

Inicio de
CAL

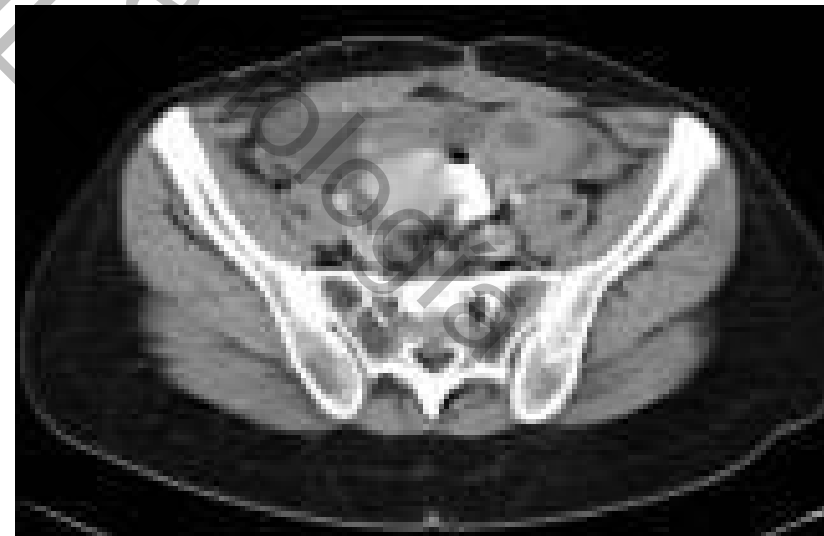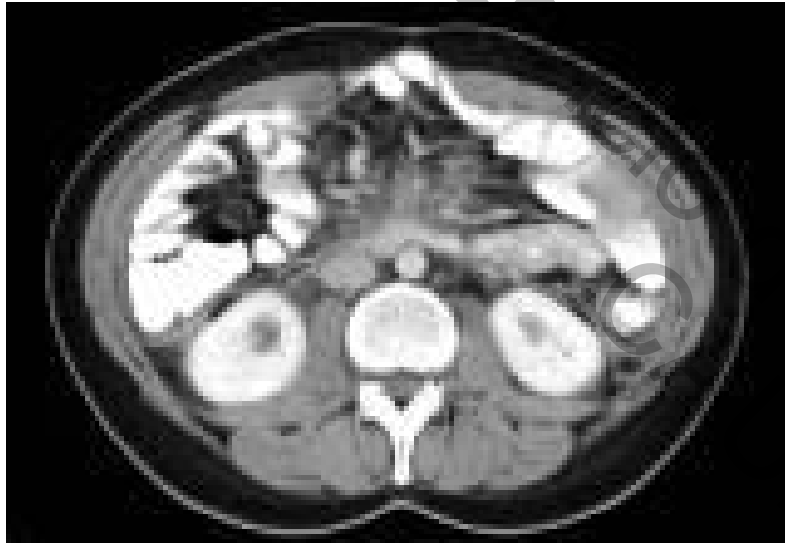logía

10/2003

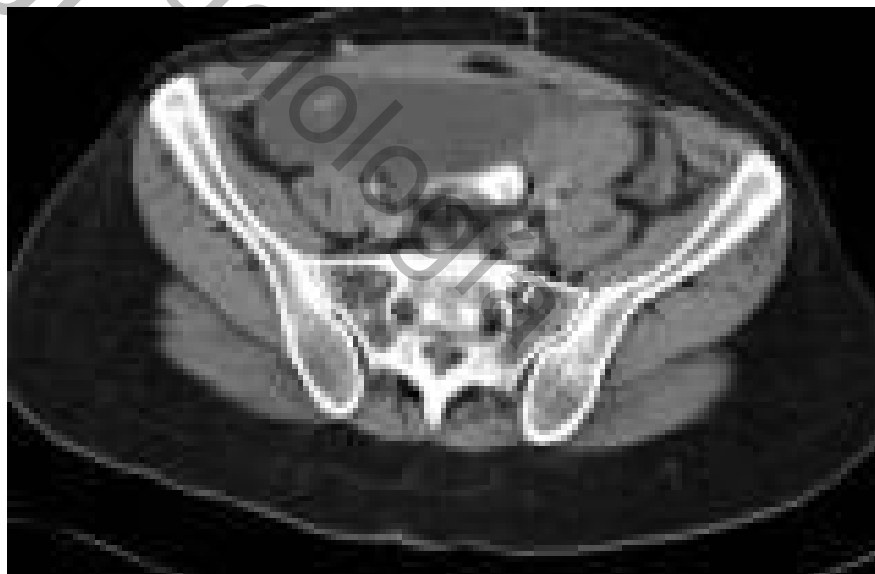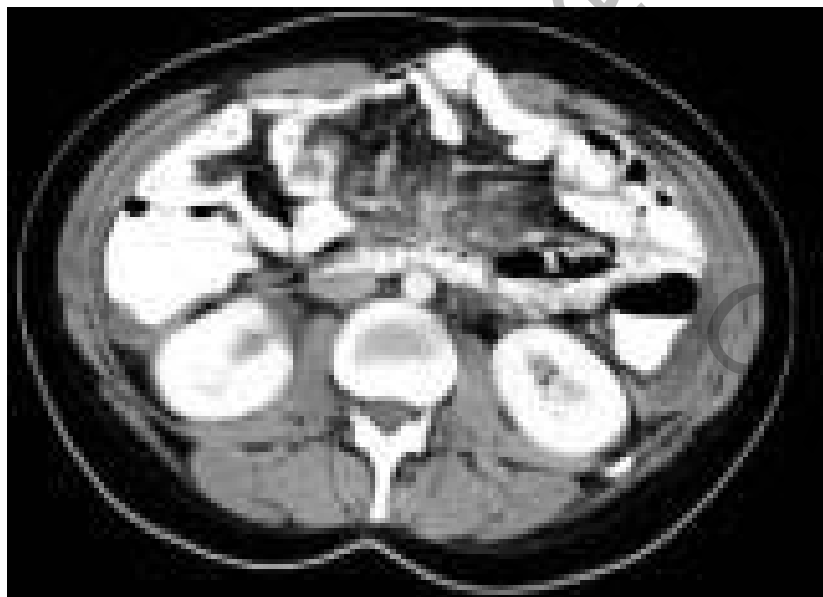Serv



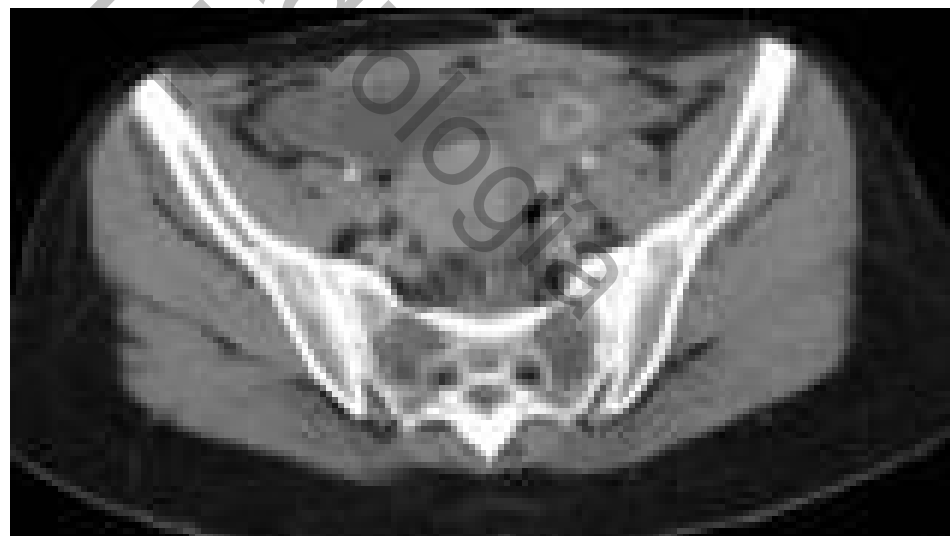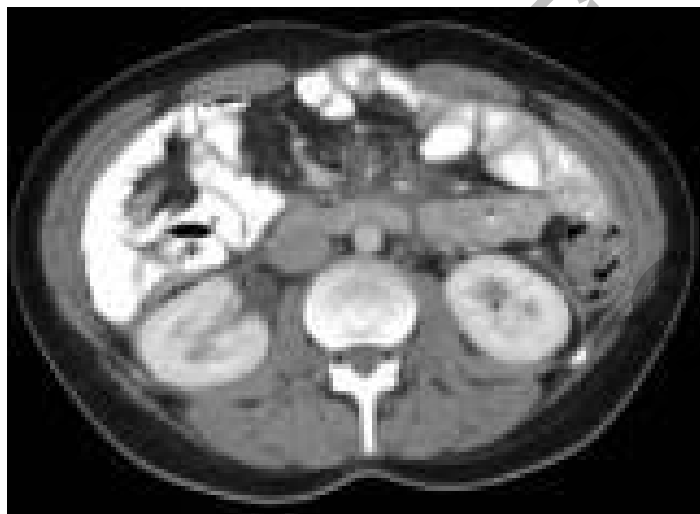
2005



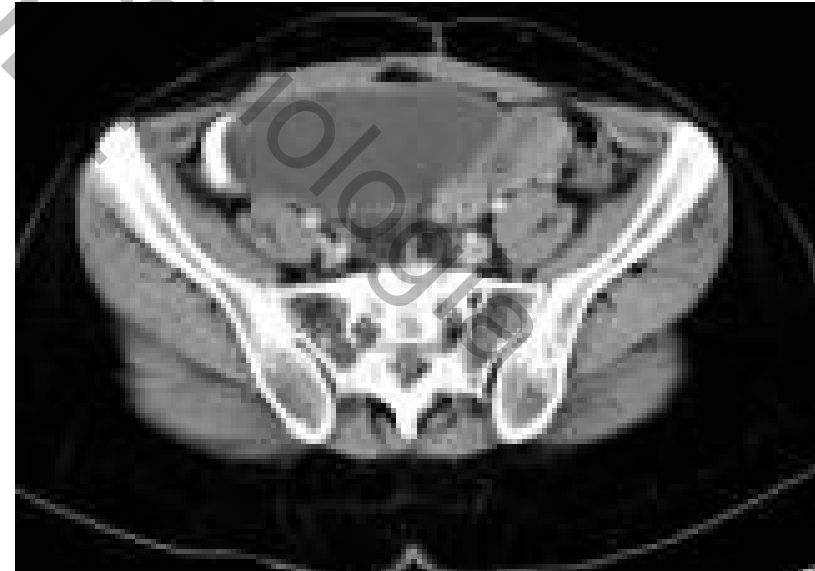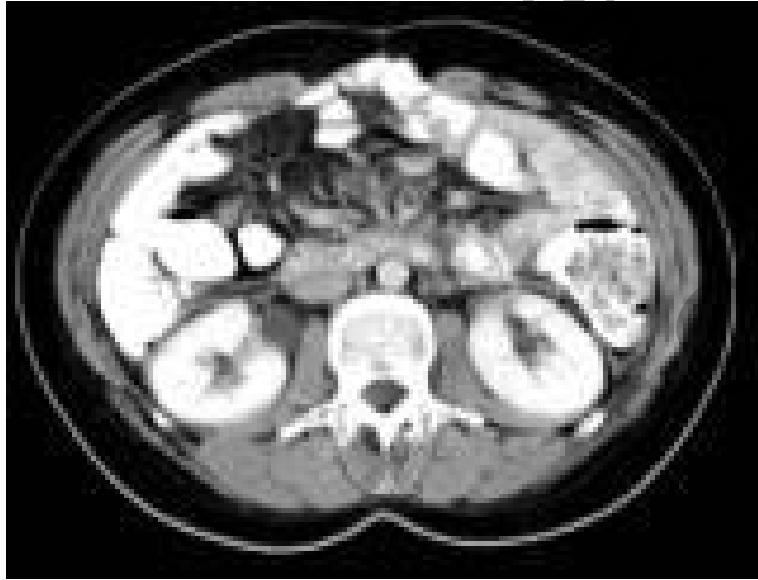
2006



2008



2009



2010

